



Dr. Sanjay Arora A regular feature is being brought to the readers of Famdent, where you can ask questions to Dr. Sanjay Arora, an eminent Implantologist, Endodontist, Occlusion specialist (eminent Neuro Muscular Dentist and a Cosmetologist. His clinic Alchemist Dental and Cosmetic Research Institute redefines "The state of the art" in India. A trainer, thinker and an ace clinician acclaimed by international researchers, Dr. Sanjay Arora will try solving questions in these areas at a very basic level of understanding for Famdent readers. Send your queries to alchemistdental@gmail.com or facebook page "Alchemist Academy for Dental Education", a site for postgraduate level participation into dental discussions and publications. The focus of this article would be NEW TECHNOLOGY IN DENTISTRY.



Dr. Rashida Ali is a renowned Cosmetic Dentist, heading a leading chain of dental centres, DENTZZ. Apart from Cosmetics, Botox and implants, her most important area of focus remains- Dental Occlusion, Neuro Muscular Dentistry and Cranio Sacral Dentistry. She has fast emerged as a sought after keynote speaker on the subject. TMD, today being recognised as the most important disorder, in causation of several body disorders, is mastered by her. This places her formidably amongst the best "Full Mouth Rehabilitation Dentist" in the country.

Bruxism - First Complete Cure In The World, Republished.

Note: Author feels Einstein was always right. If you have understood something you can make a 6 year old understand it easily. He feels medical literature is unnecessarily taught in a very complicated web of definitions and simplifying the knowledge is not attempted at. We must promote education in a manner that makes Doctors think. Many years ago, author had published this data on Facebook and has been speaking on this topic for more than a one and a half decade. But sadly very few have woken up to it. Einstein was also correct when he said no to any peer reviewed publication, he would write to the editor, that if you are going to peer review, please don't publish it. His rationale - how would you produce a peer (equal) of a highly evolved data. Two of his articles that were rejected by people no less than Neil's Bohr, himself a Nobel laureate, went to win Nobel Prize. Imagine! where would have the World been had the theory of relativity been junked.

A relatively simple disease to manage which has confused almost all the Dentists and Medical Doctors worldwide. Dr. Sanjay Arora's techniques make it simple to cure disease.

Basically it is grinding of teeth. Actually, it refers to essentially spontaneous contraction of the muscles of mastication in a manner that it leads to grinding of the teeth. Some added clenching to it. I would suggest "Clenching" is a separate disease. Mostly night grinding, but day time grinders are also seen. Most have tender and tired muscles when they wake up. Some go on unconsciously. It can be sometimes a terrifying disease. It can make one go so crazy and conscious and tired that it's no joke. On top of that these patients undergo so much stress because no Dentist or Doctor really understands this disease and they call it stress. Poor stress, it's blamed so much. There probably have been few who would have thought about ending their life due to this disease. Good news is it's the simplest of the disease to cure.

Accompanying problems are tooth sensitivity, food impaction, neck and upper shoulder pains, tongue, TMJD, Sleep Apnea and literally what not. Some say apnea is the cause of bruxism and vice versa. In short, more the curers more the versions.

As a treatment they offer, exercises (which probably never work), cold and hot fomentations, relaxing baths, splints (innumerable types), psychological therapies, long acting lateral Pterygoid blocks, etc. etc. in short they don't know the cure. There must be other cures proposed but the purpose is not to go into what is already known.

(Author once attempted to put it on Wikipedia, the moderator rejected it saying, it's not published in peer reviewed journal but a non-peer reviewed and hence rejected it. Read the note above.)

Cure: Please consider the following points, which can promote thinking.

- No other muscle in the body bruxes, except under extraordinary circumstances, like you are made to hold a heavy weight in a stretched hand, with a gun to your head for an extended period of time. Your arm muscle will have contractions even after you have left the weight.
- How come the patient was alright till a certain age? Some argue that even children grind. I remember a seminar almost 13 years ago, in Mumbai, where a leading implantologist, talked about his daughter bruxing and that he was worried. I told him, she must be under 13 and he was visibly surprised. Look for the answer that I gave him below.
- How come something you claim to be an involuntary bruxing of muscles, mainly at night due to relaxation after overwork and involves production of a resultant loud annoying crackling noise, can't be produced by a non bruxer in the day time? While a bruxer when asked to make that crackling sound that can be heard a few

feet away, will do so easily, voluntarily. Try try hard is the challenge that I have been throwing to Dentists in my lectures and no non bruxer has been able to brux his teeth. Million dollar question is if you shake your hand unconsciously, so can you voluntarily. Why can't you do that in Bruxing?

If you have really thought about it, you should have gotten the answer by now.

The answer is very simple.

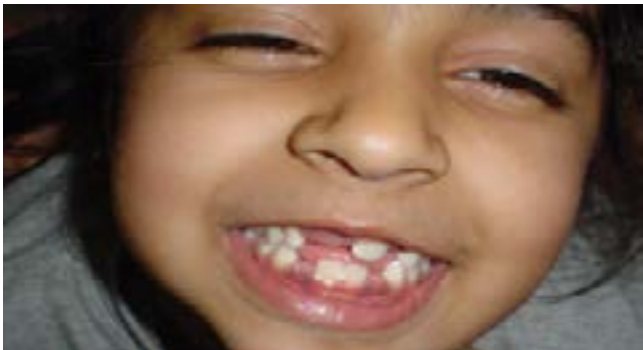

Fig. 1 Doctor, my child goes clickety clacking her teeth in the night. What do I do?

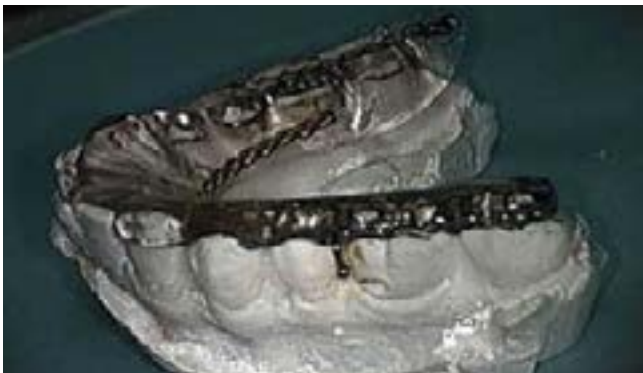

Fig. 2 Various types of unnecessary guards exist.

Now You Can't



Fig. 3 If you have this relation both anteriorly and laterally, essentially laterally with zero overjet throughout the 3mm overbite recommended.

Now You Can

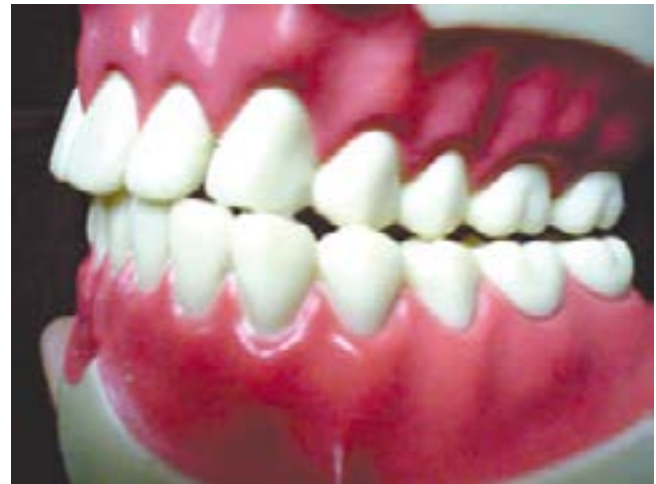

Fig. 4 If you have Canines with lost tips or misplaced Canines that is if they don't tip against each other during lateral excursion, due to wear of tip or palatal surface, along with other factors listed on left - You brux.

Consider Situation 1

Doctor, my child goes clickety clacking her teeth in the night. What do I do? A common complaint of a concerned mother. Answer by the Doctor - all of the above. Some books even say "Please take her to a physician or a gastroenterologist."

The pictures above and the explanation speak a thousand words. This is the recipe to complete cure.

- If the Canines are misplaced, bring them to correct position, Orthodontically or tip them with a crown, if it's just a slight misplacement.
- Most require a capping or crowning on all these anterior or canines' teeth as to achieve the right pressures in the glide is not easy with Orthodontics.
- Anteriors are angular teeth, designed to take angular loads. Bruxing loads are angular and must be handled by them, mostly the Canines. Lengthening only the canines by restoring the tips only in the canines is counter productive in the sense it leads to unesthetic facial smile owing to concomitant supraeruption.
- The Upper and Lower Canine complex must ideally be shifted towards the midline just a little ideally before attempting to crown them, in order for an early Disclusion. The reason is that upper palatal surface of canine has abraded along with lower canine buccal surface. Lower canines move simultaneously into this gap, not leaving a trace of space that must be recaptured. This is facilitated by the tongue pressure.

- The same can be attempted marginally for anteriors. If patient had an overjet or an inadequate overbite or an openbite or canines which were misplaced, warn the patient of few months of teeth entangling, possible breakage as neural reconnections take time. Most patients in authors experience settle down in less than 6 months with the new bite. To prevent breakage of ceramic material of the crowns, author recommends a conscious eating by the patient for a few months.
- Bruxing stops almost immediately. Some patients require an extreme guidance control, which involves use of T-scan, Biojva and BioEMG.
- Patients with huge posterior attrition, with Arora's number*, lesser by 2 mm of the normal, should be taken up for FMR or

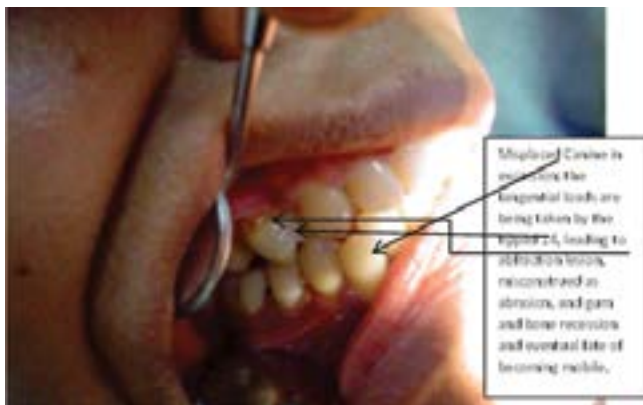


Fig. 5 Misplaced Canine in excursion: the tangential loads are being taken by the tipped 14, leading to abfraction lesion, misconstrued as abrasion and gum and bone recession and eventual fate of becoming mobile.

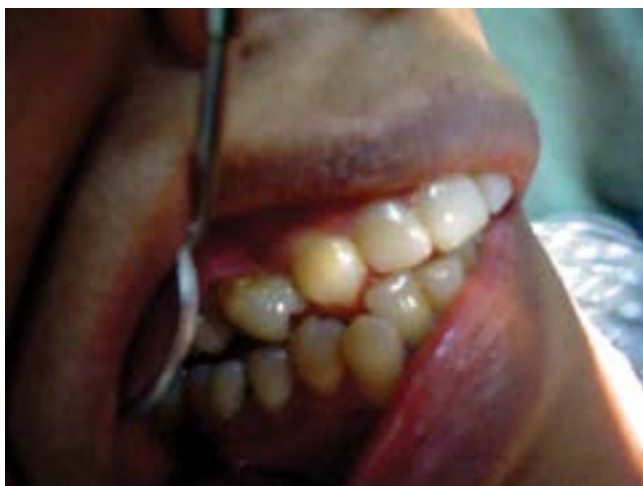

Fig. 6 Extreme excursion shows how 14 is doomed because it's playing for long the role of canine, which was supposed to do this dirty work. That's why canine was designed the longest; most curved and placed at the most curved part of the arch. This arrangement continues to push or place 44 lingually.

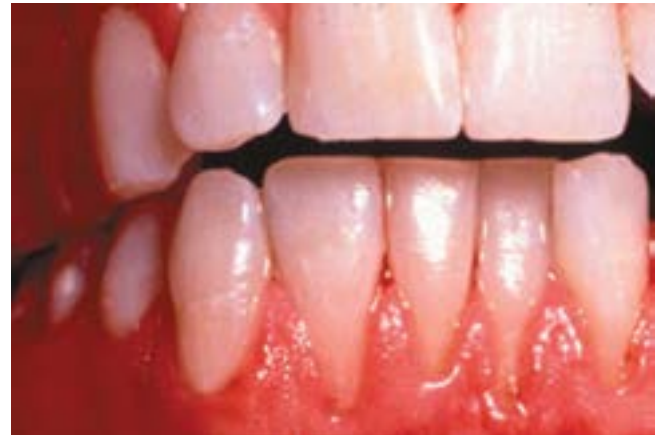

Fig. 7 Anterior and lateral grinding both possible, as there is no stop for grinding. Hence Dr. Sanjay Arora recommends Zero Overjet of the type of "Zero" called "Arora's Zero Overjet"- where entire 3mm of proposed "Arora's Overbite" is having Zero gap between the Upper and Lower Anteriors, with Pressures as recommended by "Arora's Anterior Guidance" Principles, which requires a T-scan, BioEMG and Biojva combine only.

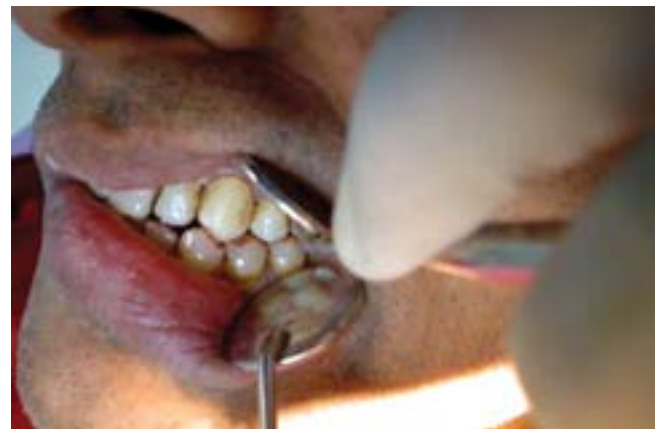

Fig. 8 Canine Guidance under correction. The lower canine distal slope meets the upper canine mesial slope during excursion. In spite of adjustment not enough guidance.

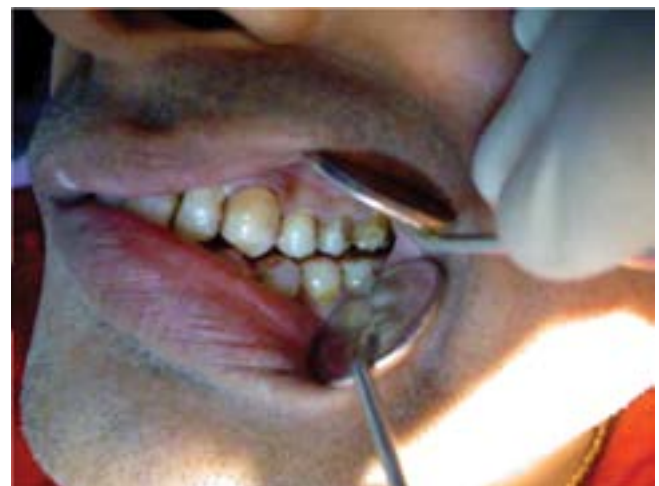

Fig. 9 Esthetics was compromised to slightly build the slopes mentioned above to provide required guidance in this Bruxer.

preferably Cranio-Sacral rehabilitation bite proposed by the author. This takes care of Yaw, Pitch and Roll. This must accompany loss of the vertical. Vertical dimension must be guided by Arora's and Shimbashi number or preferably Arora's modified Shimbashi number*

Glossary

"Aroali's Zero Overjet"-The author and coauthor, as a result of intense debate define "Aroali's Dental overjet" as "minimum horizontal distance between buccal of lower and palatal of upper incisors or their projections as in openbite cases". This dictates the extent to which mandibular teeth need to move forward and laterally before Disclusion starts. This is contrary to authors like Dawson, who state Overjet as the horizontal distance between upper incisor edge and lower buccal surface and other state it between lower incisal edge and upper palatal surface, as this fall flats if lower incisors are tilted lingually. Author therefore recommends "Zero Overjet" as ideal to facilitate immediate disclusion. He further goes on to describe "What kind of Zero". He states it to be "Zero" throughout the 3mm overbite that he recommends, at an **"Arora's modified Shimbashi"** of 17 mm, more aptly described below as 20-3(Read 20 minus 3mm), as the anterior Vertical Dimension" and with pressure recommendations as described below in **"Arora's Anterior Guidance"**.

"Arora's Overbite": This is recommended to be 2.5-3mm, by Dr. Sanjay Arora. The rationale being, that the way to check anterior guidance by asking one to protrude and check Disclusion is absolutely wrong as this motion is never done in nature. It's the incursion where anterior guidance plays a role (parameters described in **"Arora's Anterior Guidance"**) and not excursion which anyways becomes zero because of zero overjet recommended by Arora. So this is in conjunction and not independent of Overjet, to be more specific zero (unlike literature which agrees to 2mm overjet, with a wrong definition of overjet) throughout the overbite. Most people will argue that 1.5 mm to 2 mm is enough to cause posterior disentanglement, but this is not enough to provide anterior incursive guidance.

Hence its strongly recommended, that the entire thing be described as **"Arora's Anterior Relation"**, where Arora's -Overjet, Type of

Overjet, Overbite, Anterior guidance parameters described at the **Arora's modified Anterior Shimbashi number** and **"Arora's posterior Vertical Dimension"** number, with 10-20 degree proclination to the vertical passing roughly through the center of upper & lower anteriors, are all interconnected and not independent of each other.

"Arora's Anterior Guidance"(AAG): Under the above mentioned **"Arora's Anterior Relation"**, the broad parameters set by Dr. Robert Kerstein, described by me further as of 100% load on anteriors on biting, reducing to less than 2%, in less than 0.2 seconds, with anteriors contacting first, as witnessed on T-scan, may be accepted as the new Definition of Anterior Guidance. It takes into account incursion only. Excursion is automatically taken care of.

In the light of above, **"Arora's modified Shimbashi"**, can be defined as vertical distance between CE junction of Incisors measured on CBCT in occlusion, or visibly if its exposed, which should be 17, plus or minus 0.5mm, with 3 mm overbite (Arora's Overbite in context to Arora's Anterior relation). They cannot be described individually. Hence 20-3 at (AAR), Arora's Anterior Relation. 20 is the average length of incisors edge to edge, 3mm is the overlap, bring it to 17/3 where 17mm denotes the vertical length of Incisor complex in occlusion and 3mm the overlap. Both are critical.

"Arora's posterior VD number", is another adjunct, needs a CBCT-in Occlusion, to measure. Author suggests to go for FBCT, with a small FOV, which is the least exposure one can do to a patient. Posterior VD is calculated by taking into account a fairly stable landmark – that is floor of the pulp chamber, which hardly changes less than 0.1 mm during life time. I propose floor of the pulp chamber of posterior upper to lower, which is a reasonably stable landmark in 1:1 ratio OPG in absolutely interdigitated position to be taken, and at molar cusp tip to pulpal floor a very stable landmark is 8.8-9.2mm. multiplied by 2 is 18. mm -2 mm overlap is 16 mm (first molar), (16-17), 2nd molar (14.5-16) posterior VD (will call it Arora's posterior VD number as I believe it's given for the first time)(patent filed). These are stable landmarks for posterior VD and one need not arbitrarily raise the bite.